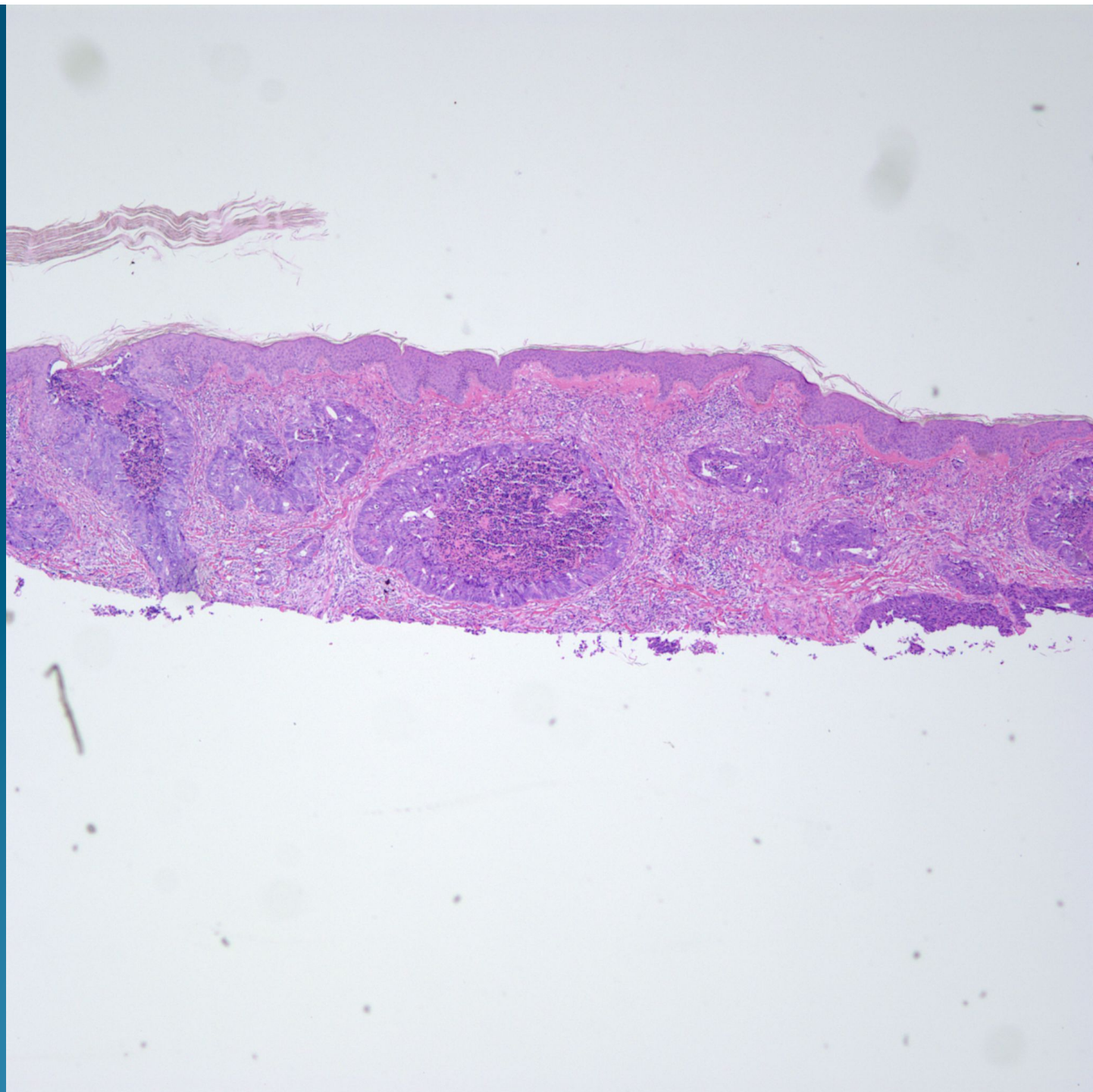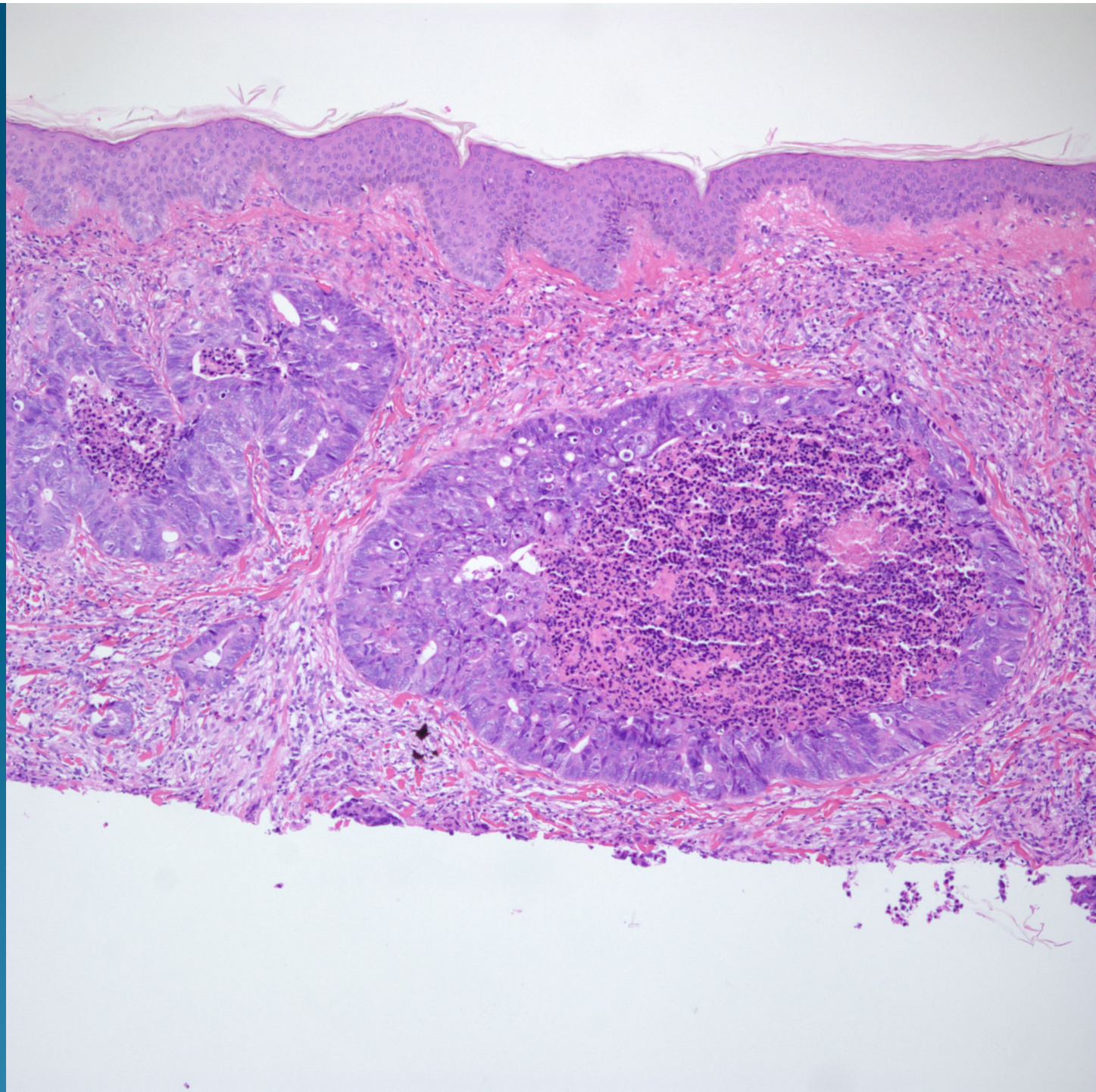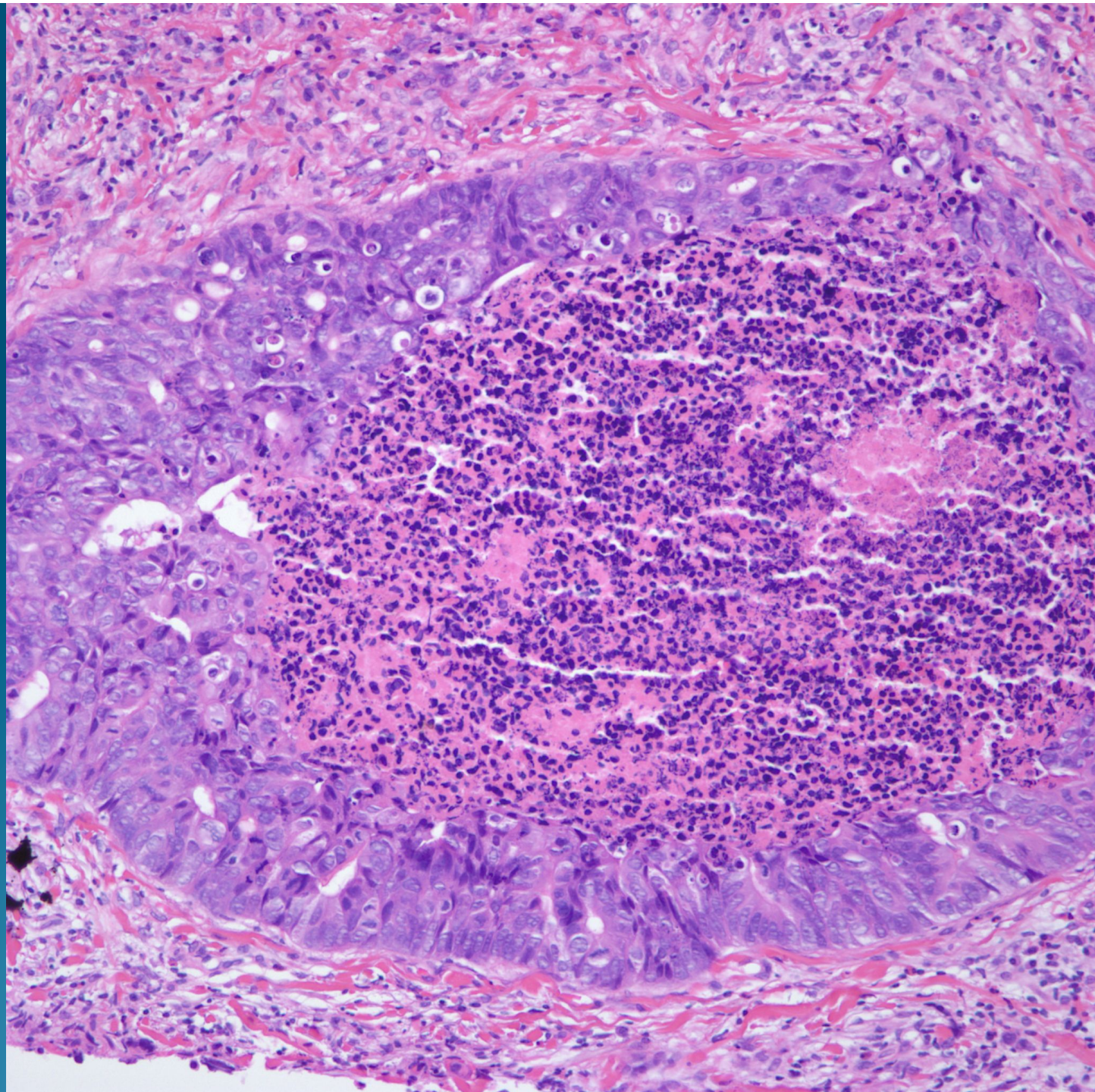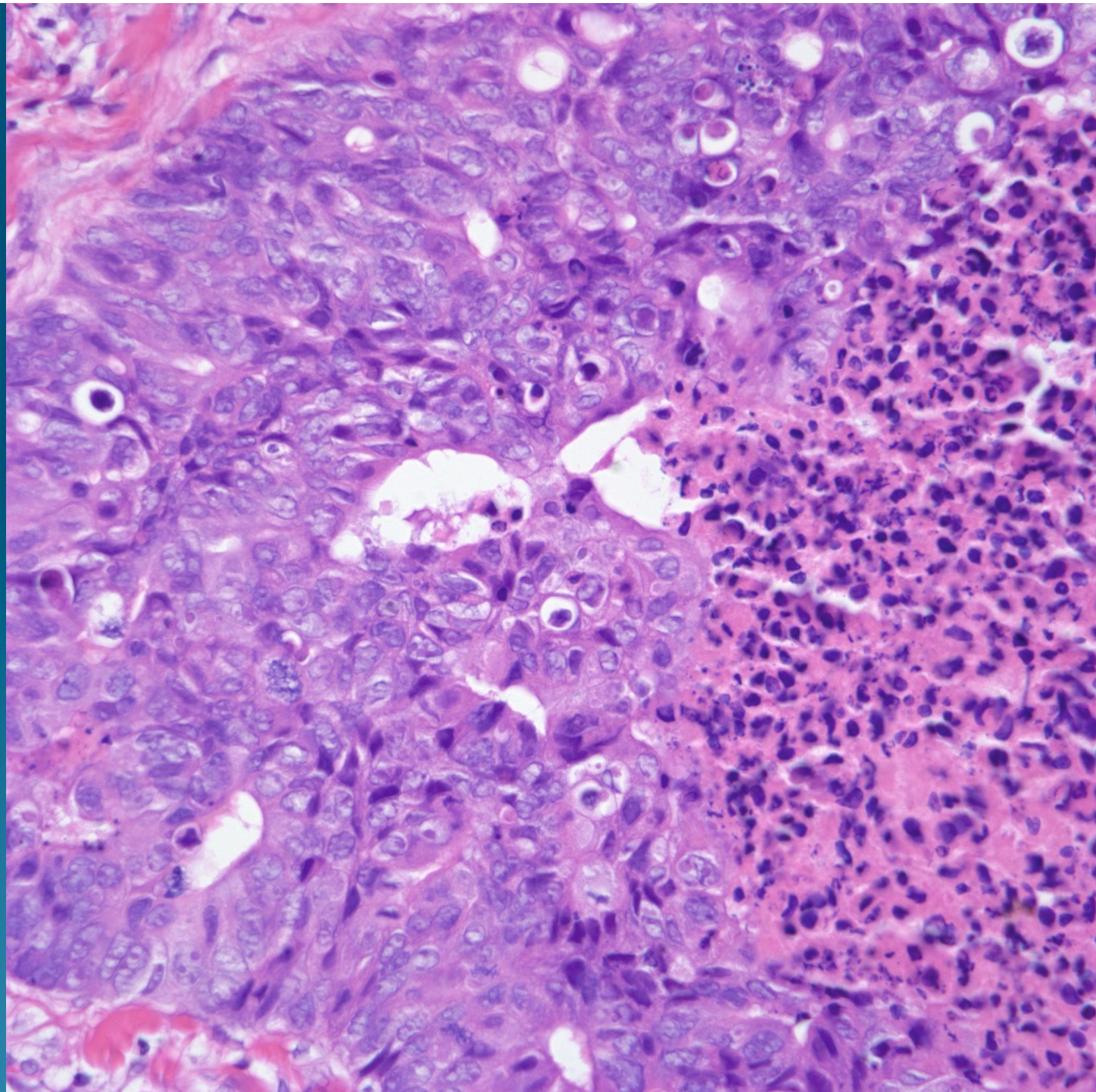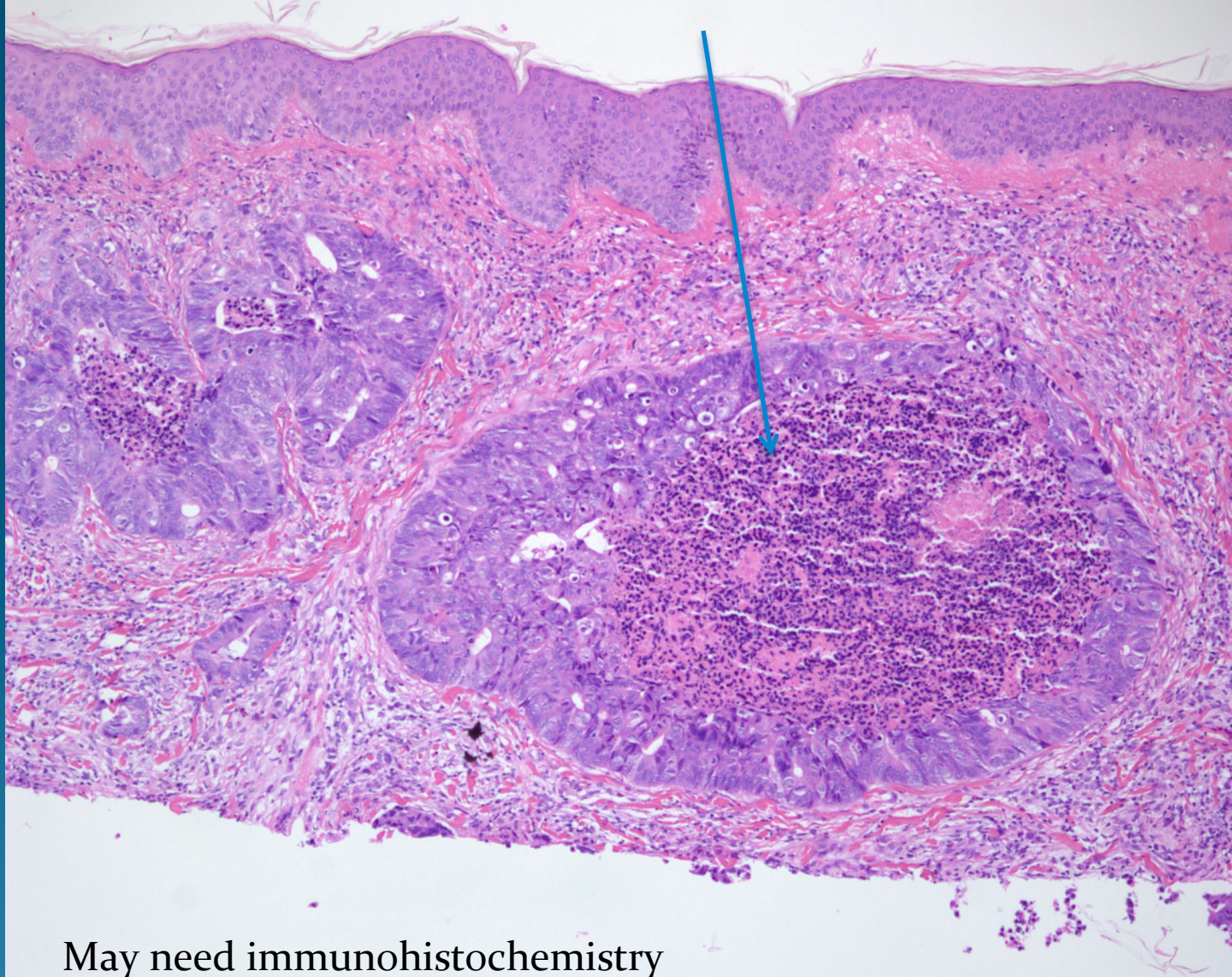


Metastatic Adenocarcinoma to the skin, consistent with Colon Primary



Malignant glands with “dirty” central necrosis



May need immunohistochemistry  
to confirm

Rarely epidermotropism by malignant glands